

Diplopia in A Patient with Persistent Coagulopathy After Snake Bite

Komal Gharsangi¹, Rajesh Bhawani², Jitender Thakur³, Manisha Bhardwaj⁴

Author's Affiliation:

¹Assistant Professor ³Senior Resident ²Professor & HOD, Department of General Medicine, ⁴Assistant Professor, Dept. of Pulmonary Medicine, Shri Lal Bahadur Shastri Government Medical College, Ner Chowk, Mandi, Himachal Pradesh 175021, India.

Corresponding Author:

Rajesh Bhawani, Professor & HOD, Department of General Medicine, Shri Lal Bahadur Shastri Government Medical College, Ner Chowk, Mandi, Himachal Pradesh 175021, India.

E-mail: rajeshbhawani@yahoo.com

Received on 06.11.2019,

Accepted on 05.12.2019

Abstract

A 40-year-old women developed right lateral rectus palsy during her course of treatment for prolonged coagulopathy following snake bite. There is scarcity of literature about prolonged coagulopathy and ever rare to be associated with neurological manifestation.

Keywords: Viper snake; Lateral rectus palsy.

How to cite this article:

Komal Gharsangi, Rajesh Bhawani, Jitender Thakur, et al. Diplopia in A Patient with Persistent Coagulopathy After Snake Bite. *Indian J Emerg Med.* 2019;5(4):249-250

Introduction

A 40-year-old female patient presented with viper snake bite leading to prolonged consumption coagulopathy and later developed right lateral rectus palsy on the fifth day.

Snake bite is an emergency situation and a threat to public health. This problem is more in the tropical countries because of their abundance in these regions. Worldwide estimated snake bite cases are 5.4 million people each year and upto 2.7 million envenomings out of which 81,000 to 1,38,000 people die each year.¹ India accounts for nearly half of all global snake bite deaths making it 50,000 deaths annually. In Himachal Pradesh neurotoxic snake

bites are more prevalent, i.e. 70% of the cases, while 30% are caused by vipers which are mostly saw scalded vipers or the Himalayan green pit vipers.² The Himalayan green pit viper presents with coagulopathy which does not respond to antsnake venom (ASV) available in India as the ASV covers only "the Big four" Indian cobra, common krait, Russel's viper and saw scalded viper.

We present a case of 41-year female patient who presented with history of snake bite to the left arm while working in the field. The arm was severely swollen up and was painful but it was difficult to associate it with local envenomation as patient had also applied tourniquet to the arm. The whole blood clotting time (WBCT) was more than 20 mins and

was administered ASV (antislake venom). WBCT was repeated every 6 hourly which remained more than 20 minutes at all times so received total of 30 vials (300 ml) of ASV, after which possibility of Himalayan green pit viper snake bite was kept and no more ASV was administered. After 4 days of hospitalization patient complained of right eye pain and double vision. On examination patient was found to have right lateral rectus gaze palsy (Fig. 2). Patient was further examined by ophthalmology department who did not find any abnormality in refraction or fundus. The WBCT of patient was monitored once daily. Diplopia started improving gradually on the second day. On 10th day the WBCT became less than 20 minutes and patient was discharged.

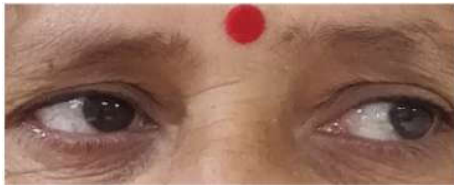

Fig. 1: Unaffected eyemovement to the left side.

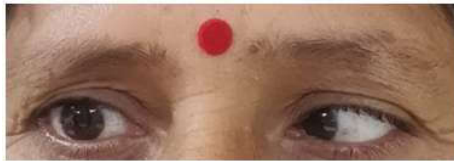


Fig. 2: Restricted movement of right eye to lateral gaze.

Discussion

Neurotoxic snake bites are known to act on the neuromuscular junction and affect cranial nerves leading to exotropia, ptosis, diplopia and ophthalmoplegia. The extraocular muscles are susceptible due to ratio of nerve fibre to eye muscle fibre (1:6 to 1:12) compared to proximal limb muscles.³ Therefore a small amount of neurotoxin can affect extraocular muscles.⁴ Ophthalmologic complications are rare in a snake bite. A case study in tertiary care hospital for ocular manifestation of snake bite showed that most of the ocular

manifestation were with viper snake bite in form of anterior uveitis, acute angle closure glaucoma, optic neuritis while cobra bites lead to external ophthalmoplegia.⁵ Our case stands different as in view of prolonged coagulopathy unresponsive to ASV possibility of Himalayan pit viper was kept which is mostly considered to have haematotoxicity and no neurotoxicity unlike other vipers. But there has not been any study on Himalayan pit viper snake bites to support our findings. Also here the patient developed extraocular muscle palsy more than 24 hours of presentation unlike other case reports where most of the palsy occurred within 24 hours of presentation.

Conclusion

Haematotoxicity and neurotoxicity is a feature of viper snake bites. Coagulopathy due to viper snake bites respond to the ASV. Here the coagulopathy persisted for 10 days even after administration of 30 vials of ASV leaving a possibility of Himalayan green pit viper snake bite. But the clinical pattern of envenomation has not been extensively studied in these snake.

References

1. www.who.int/health-topics/snakebite/envenoming
2. Chauhan V, Thakur S. The North-South divide in snake bite envenomation in India. *Emerg Trauma Shock*. 2016 Oct-Dec;9(4):151-154.
3. Bawaskar HS, Bawaskar PH. Envenoming by the common krait (*Bungarus caeruleus*) and Asian cobra (*Naja naja*): clinical manifestation and their management in the rural setting. *Wilderness Environ Med* 2004;15(4):257-66.
4. Kim HD, Jung MS, Kim SY. Exotropia caused by pit viper snakebite. *J AAPOS* 2009;13(4):424-25.
5. Kumar KVP, S Kumar P. Ocular Manifestations of Venomous Snake Bite over a One year Period in a Tertiary Care Hospital. *Korean J Ophthalmology* 2015;29(4):256-62.